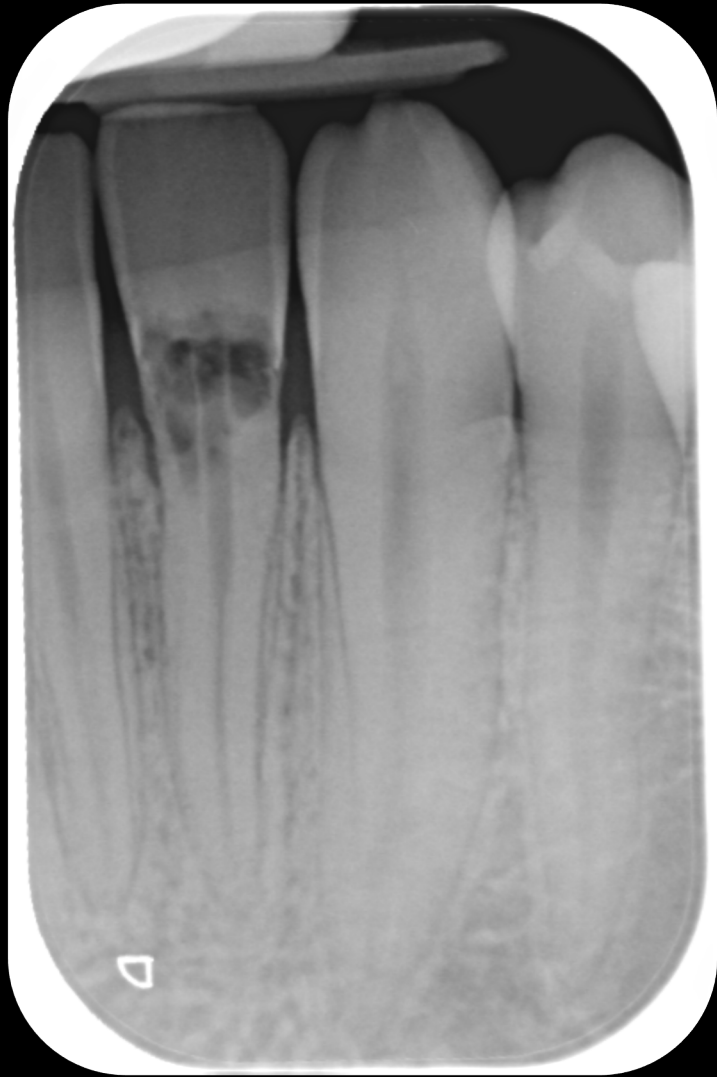



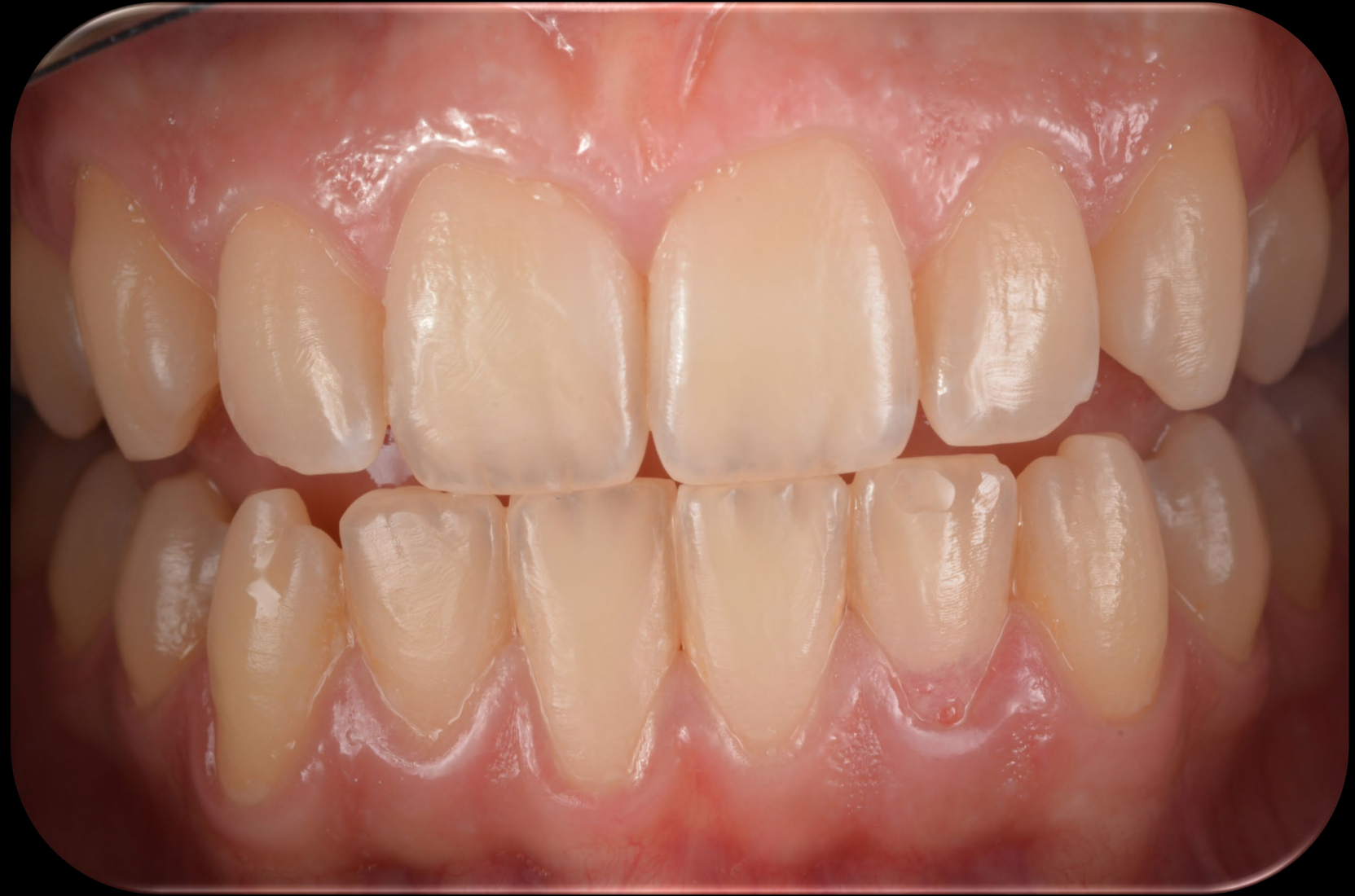CANDIDATO:
Socio Giovane Affiliato

Dott. Vincenzo Vitale

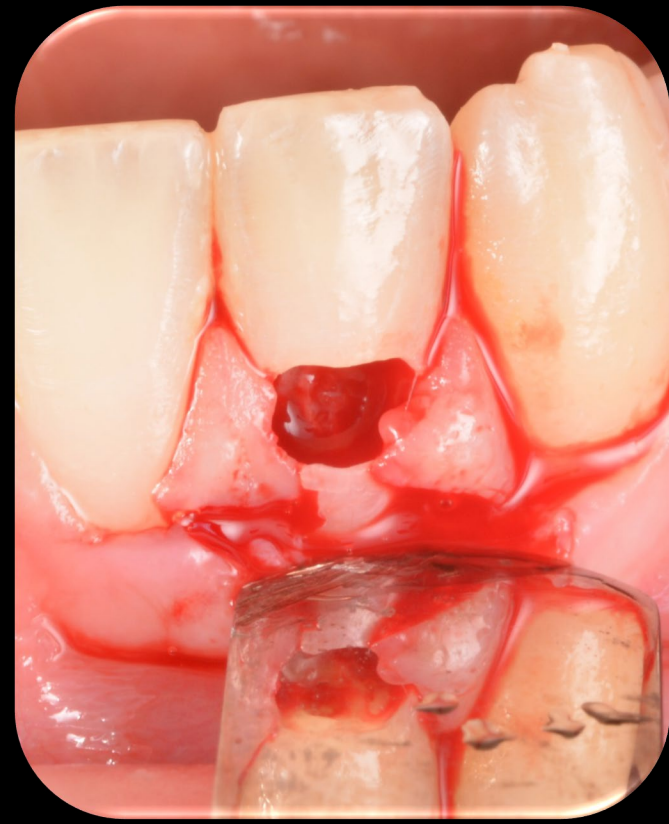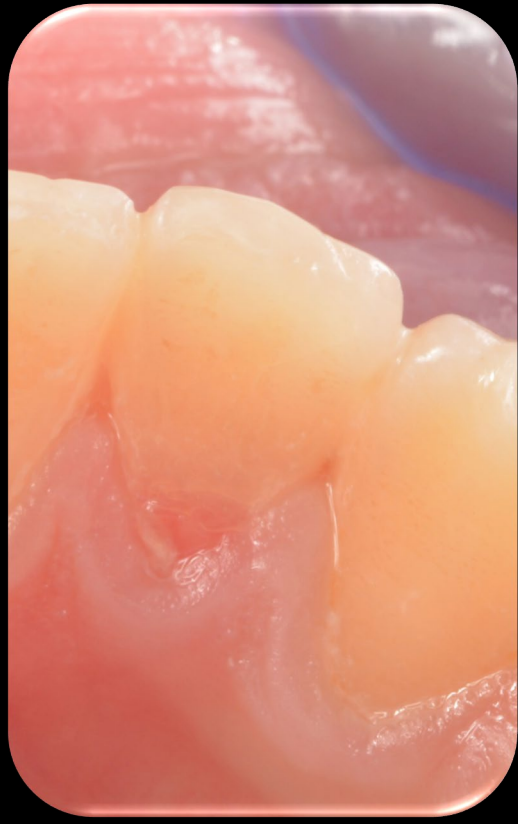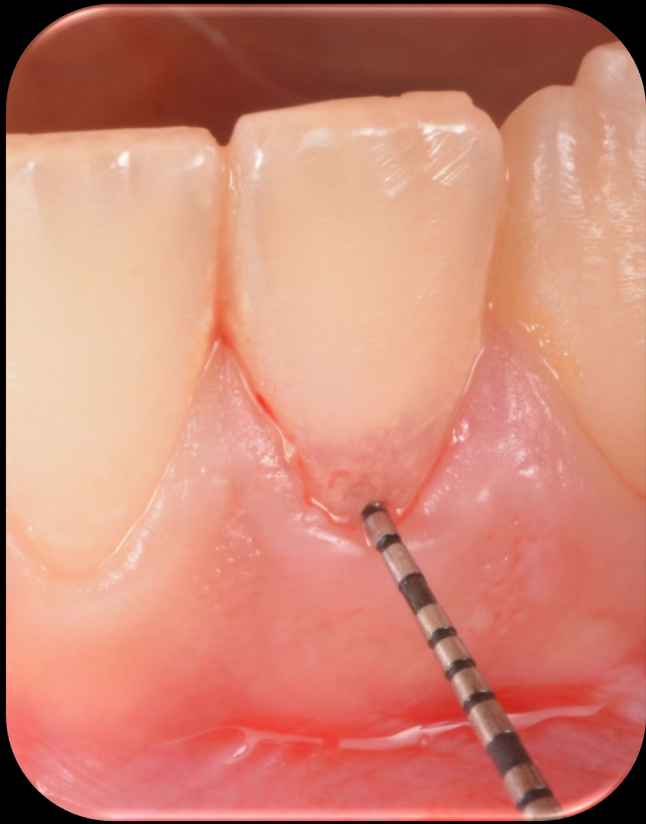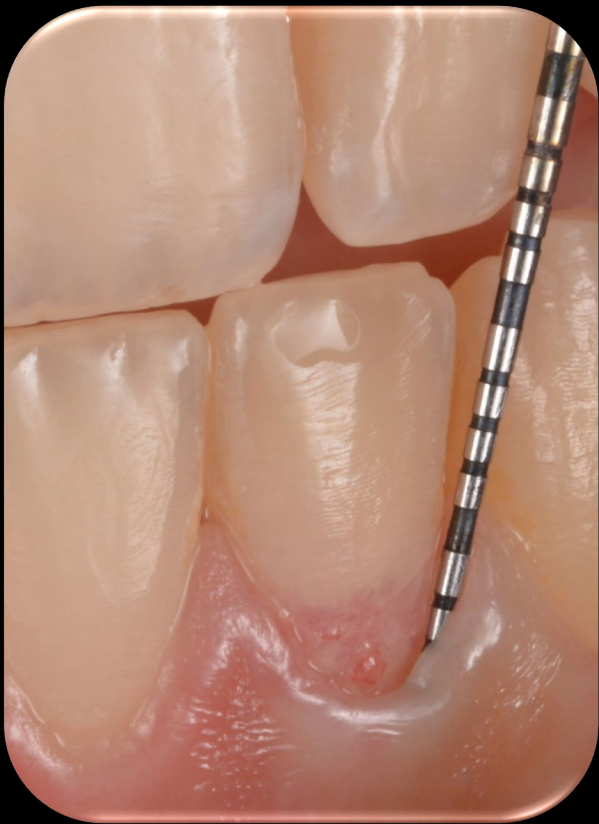CASO CLINICO



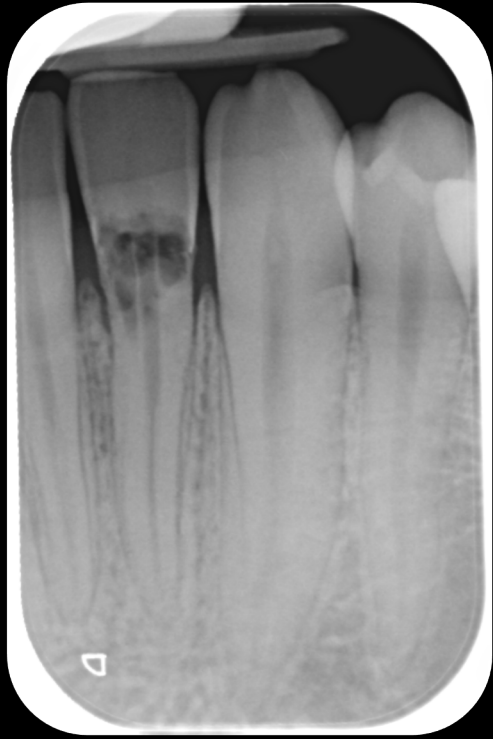T0



T0



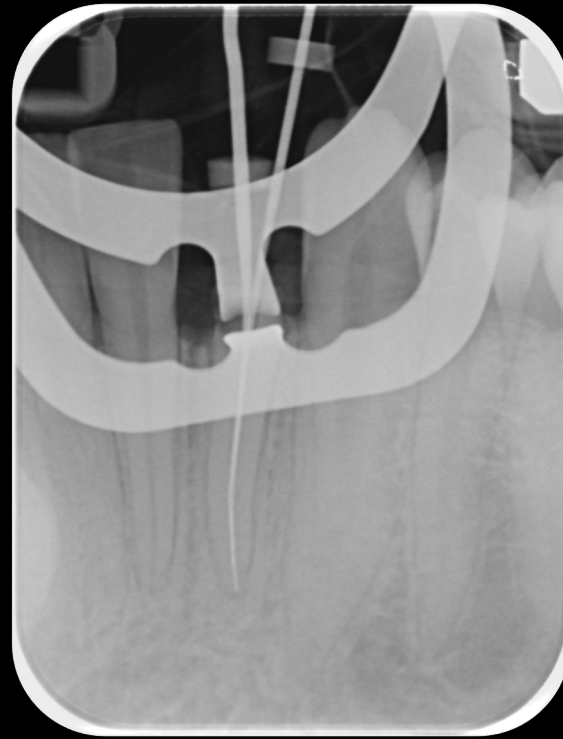
Dettagli del riassorbimento



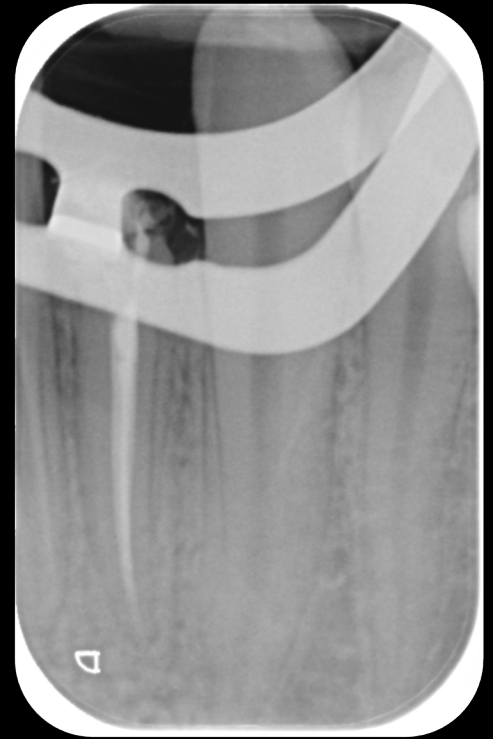T 0



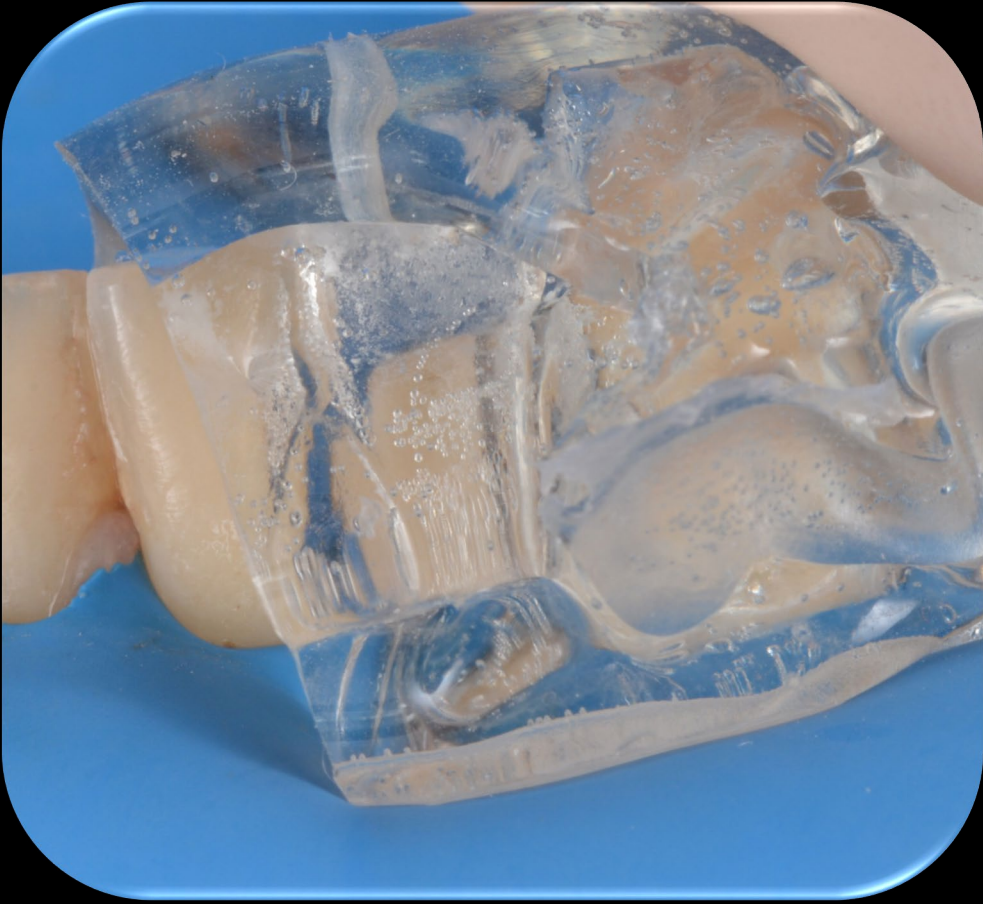apertura camera



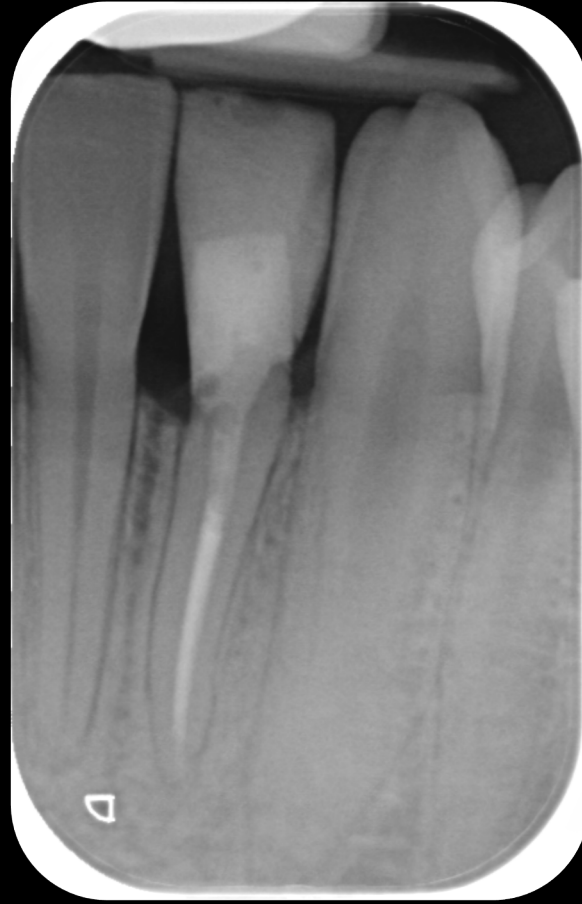L.L.



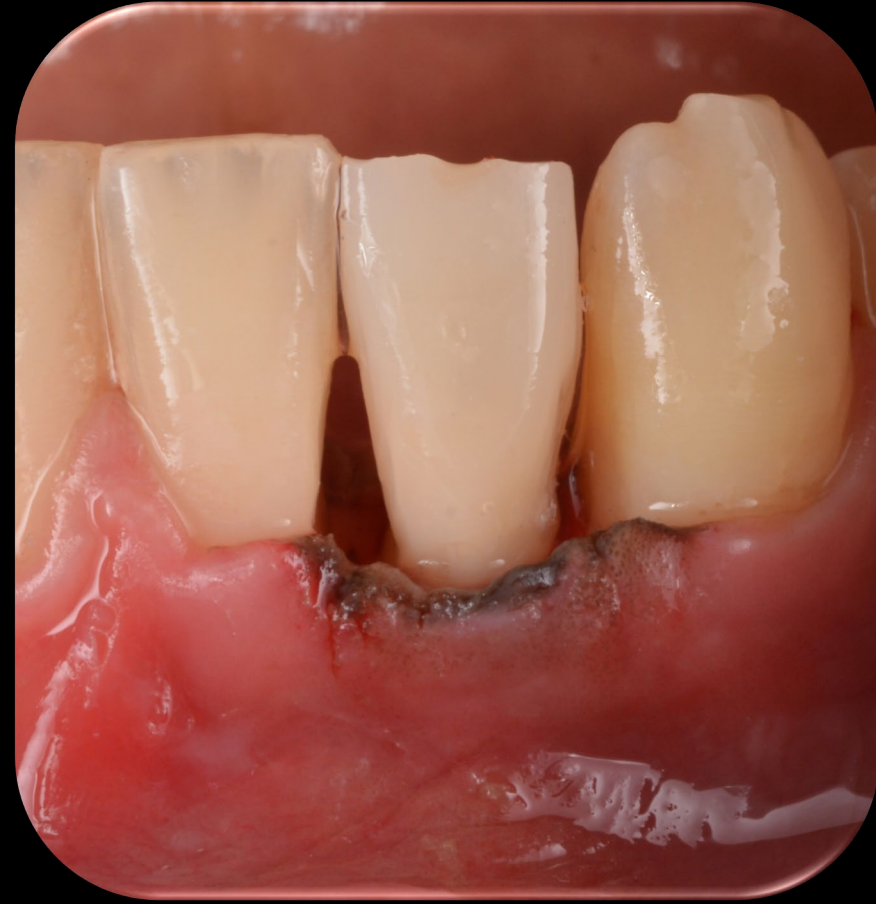otturazione canalare



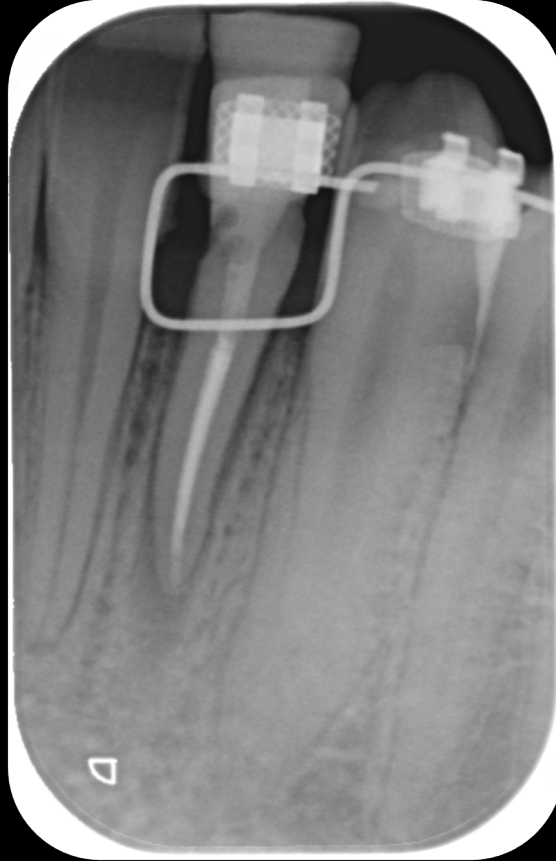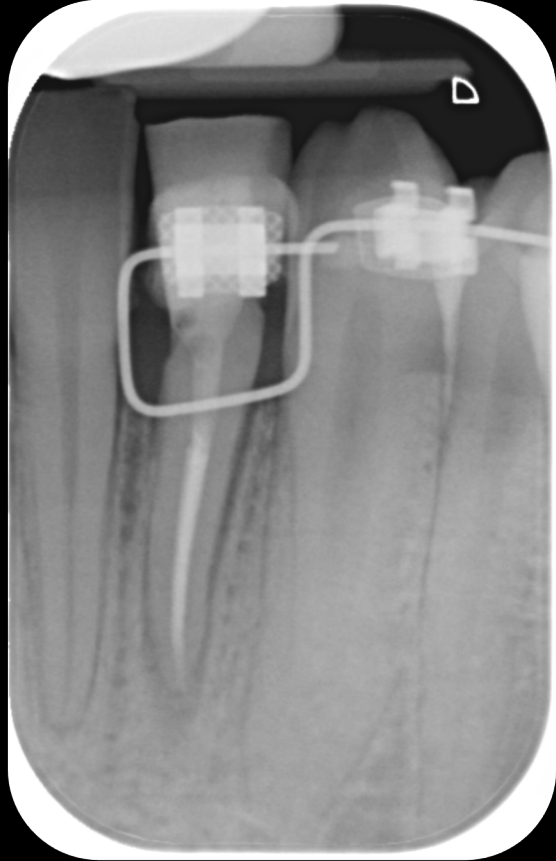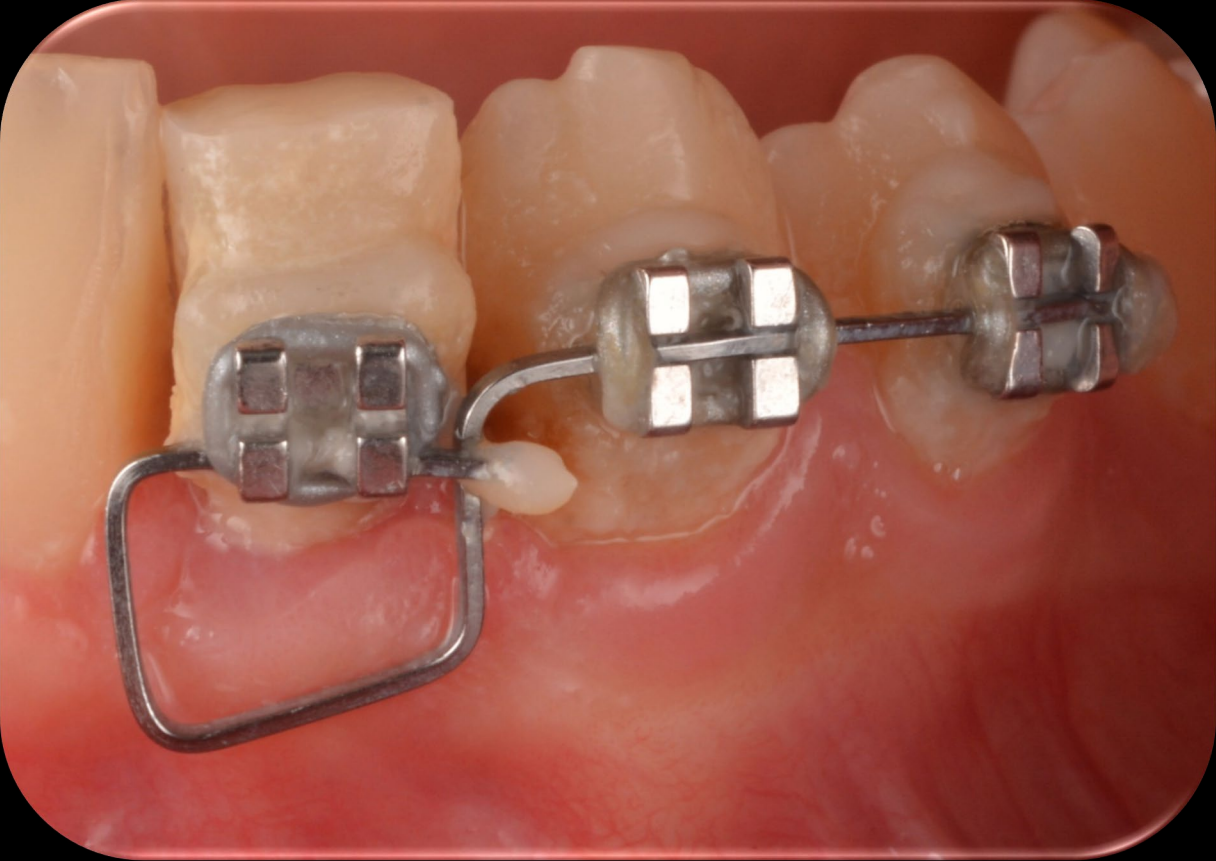
injection technique



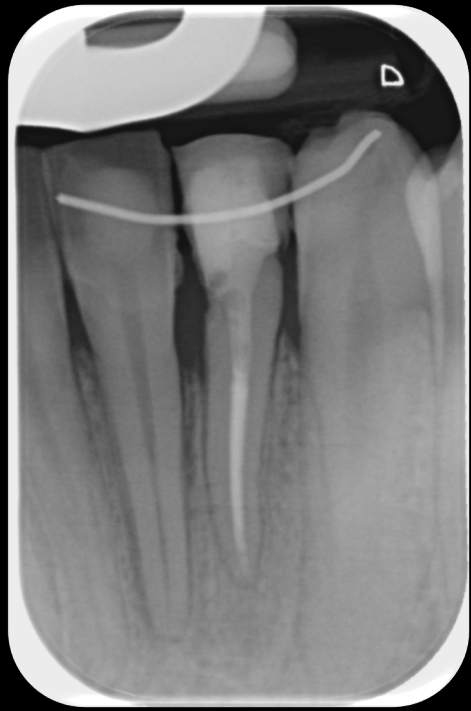ricostruzione



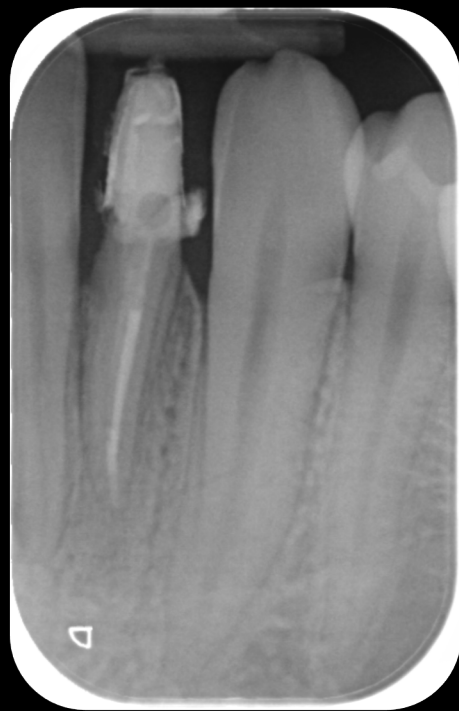post ricostruzione



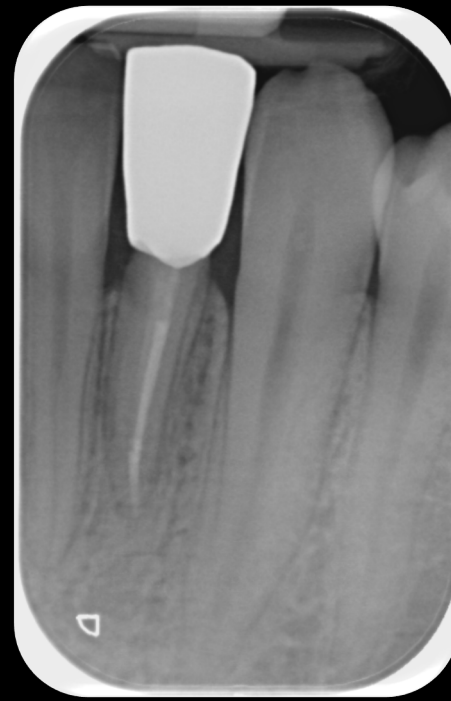
estrusione ortodontica



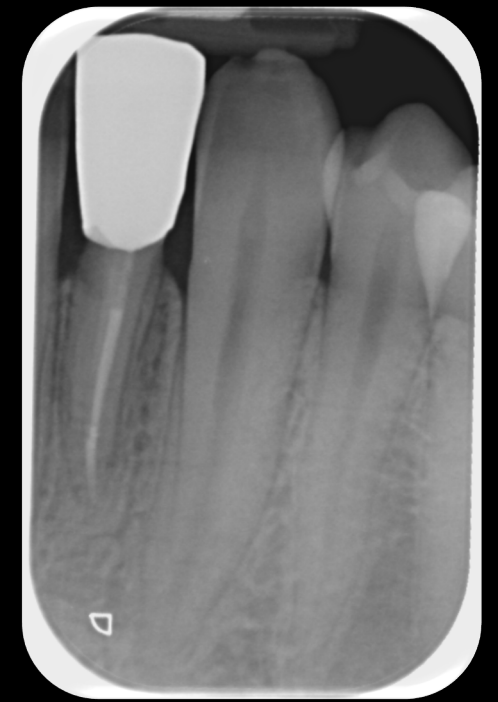4 mesi



9 mesi



14 mesi



2aa

