



Non-Surgical Endodontic Retreatment on Calcified Previously Treated Teeth with Odontogenic Fistula: A Case Report and Review

Daniyal Lazuardi Ramadhan*^{1,2}

¹ Department of Conservative Dentistry, Faculty of Dental Medicine, Universitas Airlangga, Surabaya, Indonesia

² Institute of Regeneration and Repair, College of Medicine and Veterinary Medicine, The University of Edinburgh

ABSTRACT

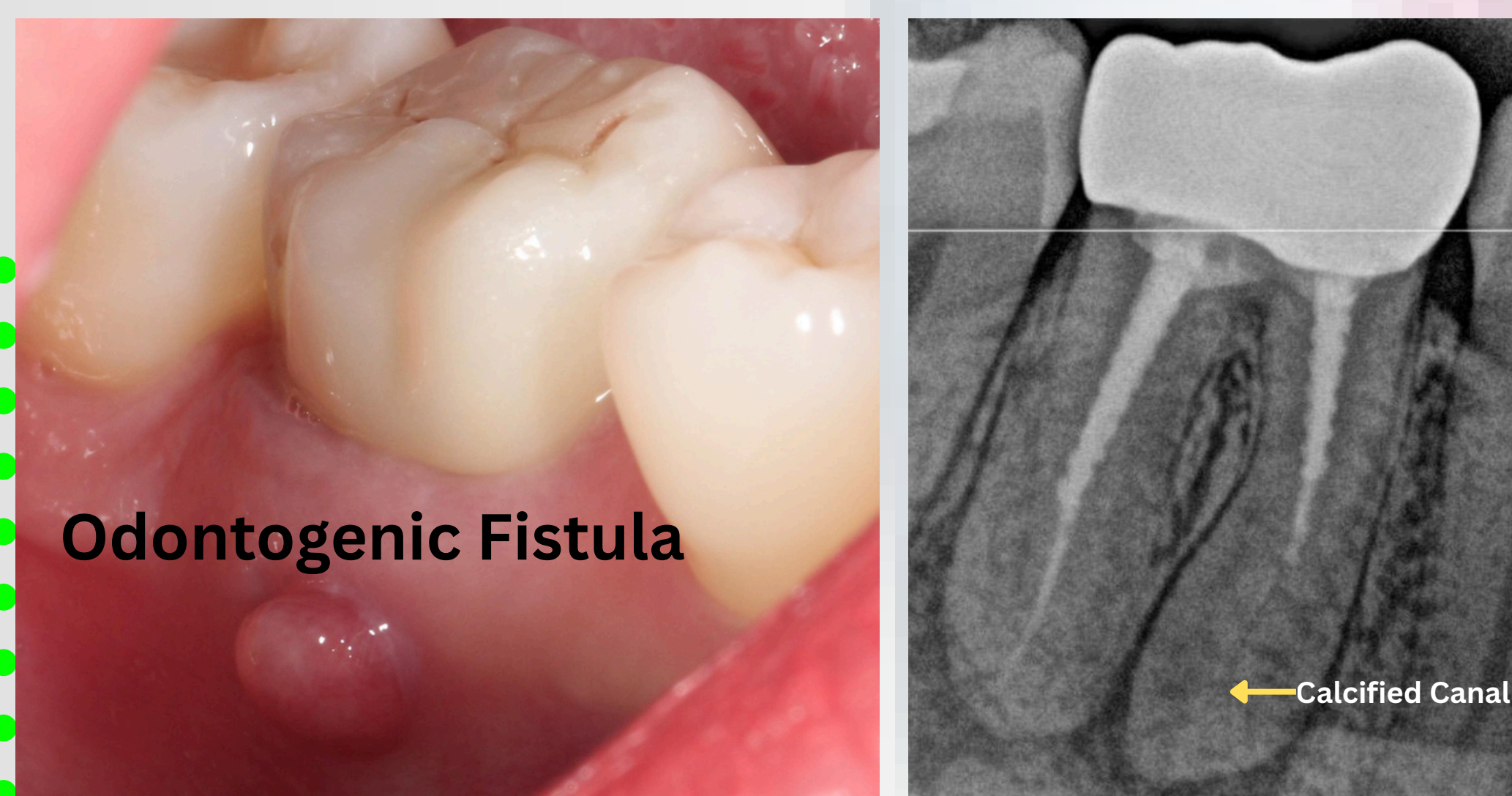
Background: Post-treatment endodontic disease often presents with persistent periapical pathology and clinical symptoms. Retreatment is frequently complicated by anatomical challenges, such as canal calcification, which hinders disinfection. This report highlights the non-surgical management of such a complex case. **Case:** A patient presented with a persistent buccal odontogenic fistula associated with a previously endodontically treated mandibular molar. Radiographic examination revealed inadequate previous obturation, periapical radiolucency, and significant root canal calcification. The condition was diagnosed as a chronic apical abscess resulting from treatment failure. **Case Management:** Non-surgical retreatment was performed under rubber dam isolation. The defective restoration was removed, and the calcified canals were carefully located and negotiated to full working length. Thorough chemomechanical preparation was utilized to disinfect the root canal system and eliminate the bacterial load. The canals were obturated, and the tooth was restored with a full-coverage crown. Clinical follow-up confirmed the complete resolution of the sinus tract and restoration of function. **Conclusion:** Non-surgical retreatment remains the primary and most conservative therapeutic modality for post-treatment disease, even in the presence of calcification and chronic draining sinuses. Successful negotiation and disinfection of the root canal system can yield predictable healing, avoiding the need for surgical intervention.

INTRODUCTION

The primary objective of endodontic therapy is the prevention and healing of apical periodontitis; however, persistent or secondary infections can lead to post-treatment disease, often manifesting as periapical pathology and chronic odontogenic fistulas. Retreatment of these cases is frequently complicated by anatomical challenges, such as pulp canal calcification, which significantly hinders access to the apical terminus and effective disinfection. While surgical intervention is an option, non-surgical orthograde retreatment remains the preferred conservative approach to eliminate infection and promote healing.

CASE

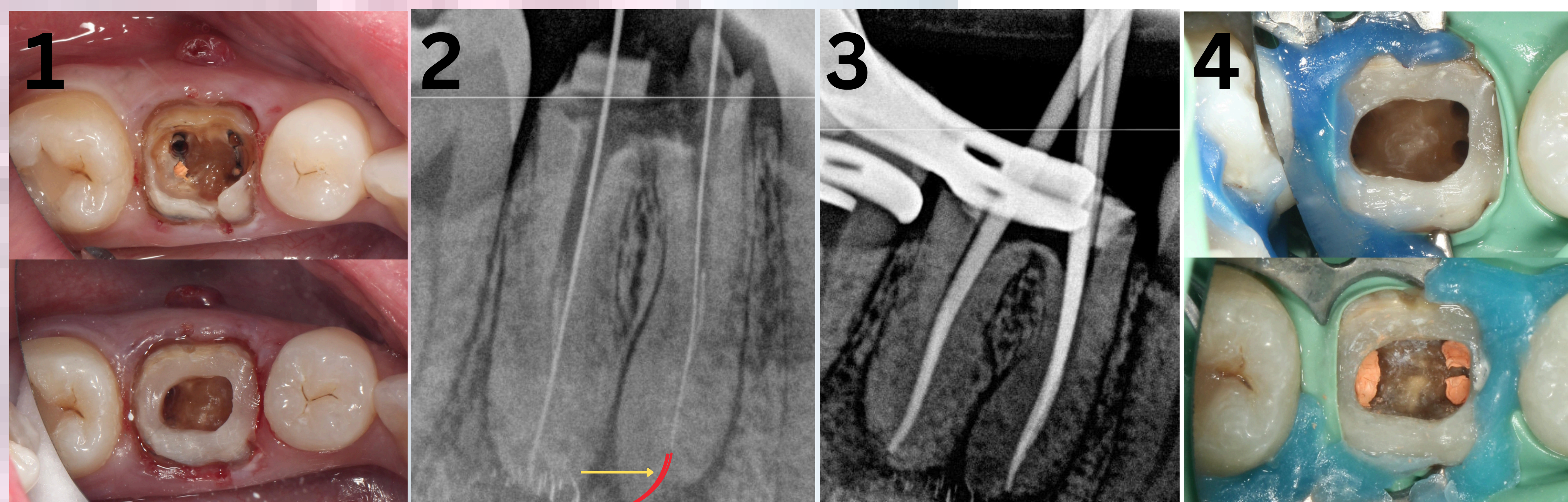
The patient presented with a small swelling on the right posterior side of the lower jaw. It was not painful, but the patient felt uncomfortable. The patient reported having had root canal treatment in the area three years ago. Clinical examination revealed a fistula on tooth 46, and radiological examination revealed a crown and screw post restoration on the mesial and distal roots of tooth 46, as well as a radiolucency in the periapical area.



DISCUSSION

The primary etiology of this treatment failure was persistent intraradicular infection, exacerbated by pulp canal calcification that hindered previous disinfection efforts. The presence of an odontogenic fistula is pathognomonic of a chronic apical abscess, serving as a drainage route for periapical inflammation; however, literature confirms that surgical excision is rarely indicated, as these tracts resolve spontaneously following effective source control. Non-surgical retreatment was the preferred conservative modality, utilizing magnification to negotiate calcified canals and rigorous chemomechanical preparation to eliminate bacterial biofilms. The successful resolution of the fistula confirmed biological healing, while the subsequent restoration with a fiber-reinforced post and monolithic lithium disilicate crown provided the necessary structural integrity and coronal seal. This case validates that even with anatomical complexities, orthograde retreatment offers a predictable and high-survival outcome, preserving natural dentition without the need for surgical intervention.

CASE MANAGEMENT

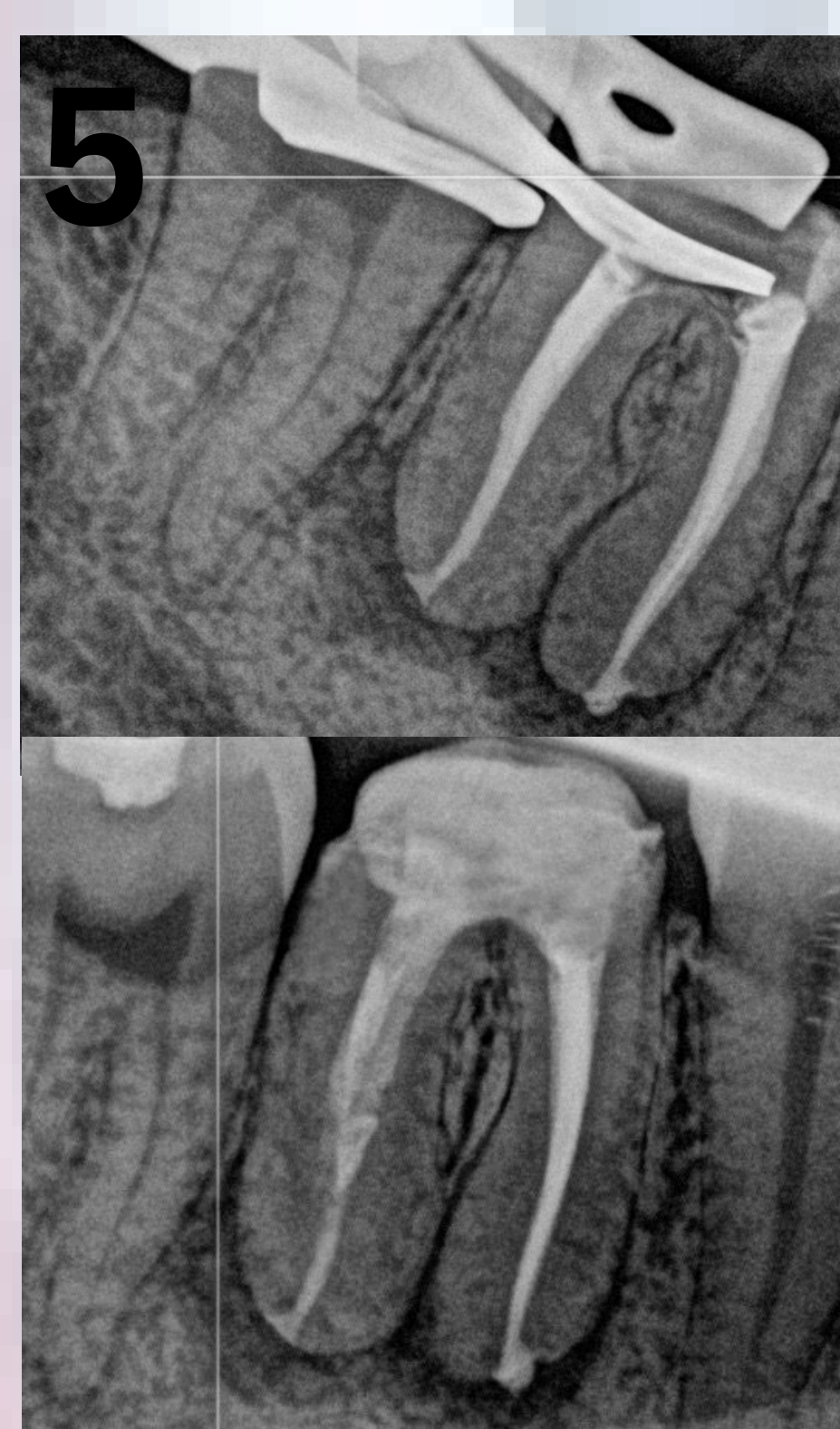

1 Crown and Screw post retrieval followed with Pre-R.C.T. Rewalling

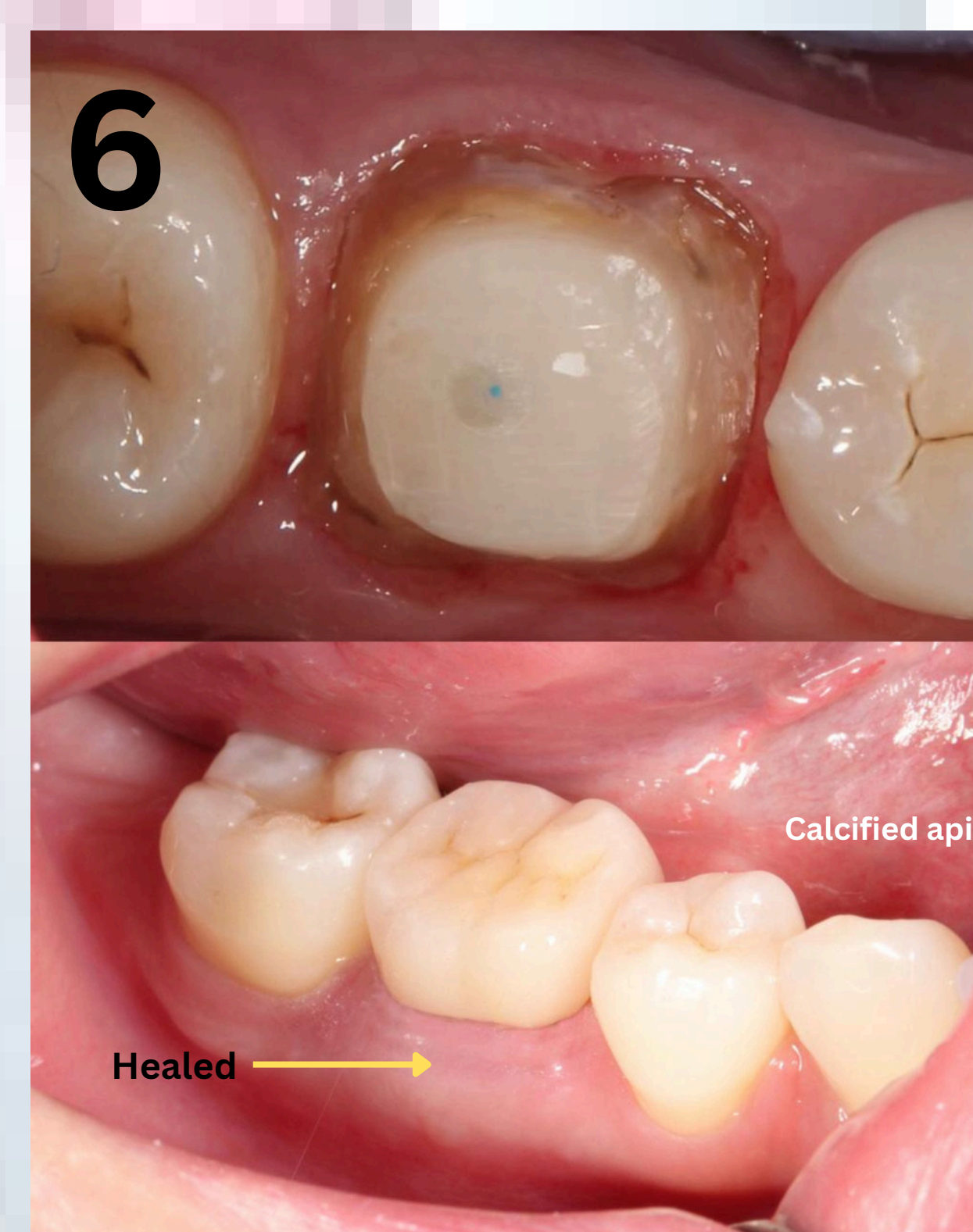
2 Negotiation and calcified on apical third of mesial canal

3 Trial GP

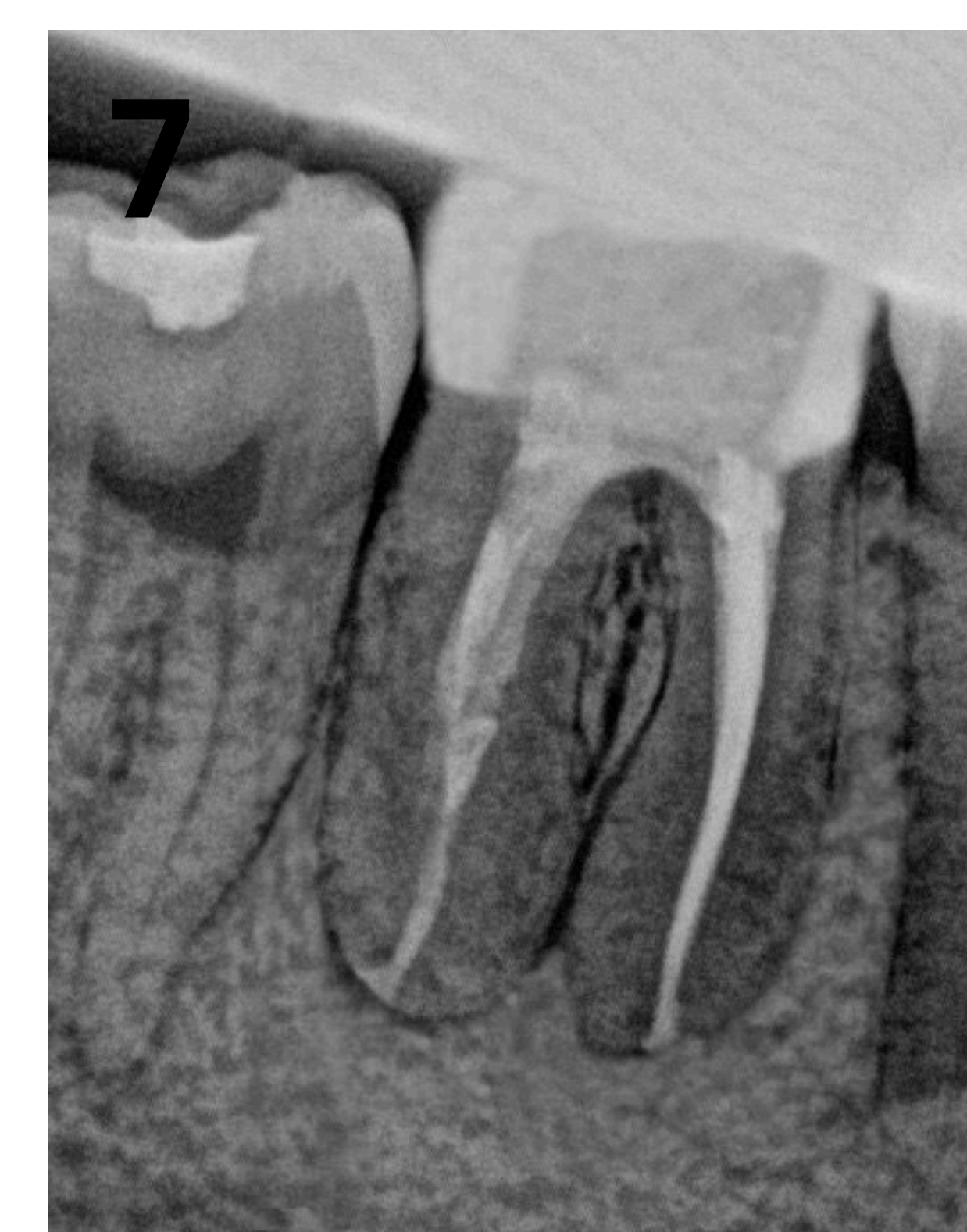4 Cleaning and Obturation



5 Radiographic confirmation of obturation and fiber post insertion



6 Crown preparation and Final result



7 1 years post control

CONCLUSION

Non-surgical endodontic retreatment is a predictable and effective approach for managing post-treatment disease, even when complicated by pulp canal calcification and chronic odontogenic fistulas. Successful healing relies on the precise negotiation of obliterated canals and thorough chemomechanical disinfection, which leads to the spontaneous resolution of the sinus tract without the need for surgical intervention. When combined with a robust coronal restoration to ensure a seal and structural integrity, this conservative modality successfully preserves the natural dentition and avoids extraction.

REFERENCES



This poster presented at