

# An *Ex Vivo* Evaluation of a Gutta-Percha Filling Technique When Used with Two Endodontic Sealers: Analysis of the Filling of Main and Lateral Canals

Mauro Venturi, MD, DDS

## Abstract

The aim of this study was to evaluate both the precision of filling and the extension of voids in main root canals as well as filling of lateral canals after using a two-phase filling technique with two sealers. Twenty-four maxillary and 26 mandibular molars were selected and randomly assigned to two groups. Root canals were instrumented and then filled using the vertical compaction with the apical backfilling technique, with Pulp Canal Sealer (EWT) in group "A" and AH Plus in group "B." After clearing, voids within the filled main canals were measured by using a stereomicroscope. In addition, visible lateral canals were counted, each unfilled space was measured, and five ratings (0–4) were fixed. In both groups, in the most apical 4 mm of main canals, where gutta-percha was cold compacted, lesser voids ( $p \leq 0.05$ ) were found than in the middle-coronal thirds backfilled with thermomechanical compaction. In group "B," more precision ( $p \leq 0.05$ ) and lesser voids ( $p \leq 0.05$ ) were found than in group "A." Regarding lateral canals, better filling scores ( $p \leq 0.05$ ) were found in group "B" than in group "A." In both groups, better filling scores ( $p \leq 0.05$ ) were found at the coronal levels than at the middle ones and at the middle levels than at the apical ones. (*J Endod* 2008;34:1105–1110)

## Key Words

Clearing, endodontic sealers, filling technique, gutta-percha, lateral canals

From Private Practice, Bologna, Italy.  
Address requests for reprints to Dr Mauro Venturi, Viale Oriani, 52, 40137 Bologna, Italy. E-mail address: [info@endodonziamauroventuri.it](mailto:info@endodonziamauroventuri.it).  
0099-2399/\$0 - see front matter  
Copyright © 2008 American Association of Endodontists.  
doi:10.1016/j.joen.2008.06.017

Endodontics concerns the prevention and treatment of apical periodontitis, and key to such treatment is cleaning and filling the root canal system (1), which includes one or more main canals but often also shows ramifications (2) from which it is difficult to eliminate bacteria and tissue debris with endodontic instruments. Root canal-filling procedures should be directed toward the filling of both main and lateral canals. Although Barthel et al. (3) found no correlation between unfilled lateral canals and inflammation of the periodontal ligament, other studies showed their potential pathogenicity after healing of periradicular lesions in relation with their full filling (4–6).

Gutta-percha, compacted at body temperature or plasticized by heating, supplemented with resin- or cement-based sealers, is the most commonly used root canal obturation material (7). Cold lateral condensation has proven to be a clinically effective filling technique (8), but when subjected to stress cold gutta-percha undergoes small plastic deformation and cannot move into canal irregularities (9, 10). Techniques that use heat to plasticize gutta-percha allow for better adaptation to canal walls and provide a higher degree of homogeneity as well as improved sealing of irregularities and lateral canals (8, 11), but this approach has the disadvantage of increasing the volume of the material and requires compaction during cooling to prevent shrinkage (12). Unfortunately, under compaction, amorphous gutta-percha easily extrudes (13, 14).

The "vertical compaction with the apical backfilling" technique (15) takes into account and attempts to solve these problems by combining apical compaction of cold gutta-percha with backfilling using thermomechanical compaction. Tagger et al. (16) have observed that there is an interaction between certain brands of gutta-percha and some sealers and suggested that understanding this interaction might serve as a guide for choosing the most suitable combination for each obturation technique.

Zinc oxide–eugenol cements are widely used root canal sealers because of their plasticity, slow setting time in the absence of moisture, and small volumetric change on setting. Among them, pulp canal sealer (PCS) (Kerr; Sybron Dental Specialties, Romulus, MI) has emerged as the favorite sealer for use with the vertical condensation of warm gutta-percha (7).

Epoxy resin sealers provide reduced solubility (17), microretention to root dentine (18), and low sensitivity to moisture. AH-26 (DeTrey Dentsply GmbH, Konstanz, Germany), which has been widely used in the past, has been replaced by AH Plus (DeTrey Dentsply), having one half of the film thickness and of the solubility of the former and it does not release formaldehyde (19).

This study intended to evaluate the quality of filling provided by the vertical compaction with the apical backfilling technique when used with PCS Extended Working Time (EWT) (Kerr, Sybron) or AH Plus (DeTrey Dentsply) both in main root canals and in lateral canals.

## Materials and Methods

Pairs of similar extracted teeth with roots having a length of 12 to 15 mm without resorption, fractures, or open apices and showing narrow apical diameters were selected. Radiographs were taken in buccolingual and mesiodistal views. Each tooth within each pair was randomly assigned to either group "A" or group "B." Each group included 12 maxillary and 13 mandibular molars, with 75 canals similar in length and size, having a curvature of 0 to 50° (20). The same operator instrumented all canals under 4.3× magnification (Zeiss telescopes; Carl Zeiss GmbH, Zeiss Group, Jena,

Germany). After a conventional access was achieved, the working length was measured to an accuracy of 0.25 mm with a #06 K-file (F.K.G. Dentaire, La Chaux-de-Fonds, Switzerland) by observing its tip to reach the anatomic foramen (ie, the most outer diameter at the apical terminus of the root canal [21]) under 10× magnification with a stereomicroscope (Zeiss Stemi 2000-C, Carl Zeiss GmbH). Because of the variability of types of apical constriction (22) to the impossibility of ascertaining with complete certainty the position of the apical canal constriction during root canal therapy and achieving homogeneity within and between the groups, each main canal was enlarged exactly enough and nothing more so a continuous tapered shape could be obtained in the most apical 4 mm, with both the minor diameter and anatomic foramen (21) coinciding in one. Canals were first instrumented to working length using stainless steel Hedstrom files #8–10 (F.K.G. Dentaire) followed by a #10 0.04 taper NiTi MTwo rotating instrument (Sweden and Martina; Due Carrare, Padova, Italy). The brief manual preflaring avoided the tip of #10 MTwo developing torsion on entering canal region with small cross-sectional diameter, thereby reducing the risk of separating the instrument within the canal; #10 MTwo was used to gently enlarge the coronal and middle third of each root canal, allowing Hedstrom files #15–20 to easily reach the working length and to further prepare each root canal. Finally, ProFile .04 taper rotary NiTi instruments #15–40 (Dentsply Maillefer, Ballaigues, Switzerland) were used to complete the preparation of main canals. The apical portion of each root canal was kept free of debris by moving passively through it a size 06 K-file (F.K.G. Dentaire). All canals were irrigated with 5% sodium hypochlorite and lubricated with RC-Prep (Hawe Neos Dental, Bioggio, Switzerland).

A final 15 minutes of irrigation with a 17% EDTA solution removed the smear layer, according to Goldberg and Spielberg (23). They observed the first effects of the chelator after 5 minutes but suggested an extended working period to enhance the cleansing result (23). After completing the instrumentation, the apices of the prepared main canals had diameters of 0.20 to 0.40 mm.

After instrumentation and drying with absorbent paper points, each canal was filled using the vertical compaction with the apical backfilling technique (15). A 0.04 GT gutta-percha cone (Dentsply Tulsa Dental, Johnson City, TN) was cut 1 mm shorter than the working length, coated with PCS (EWT) cement (Kerr, Sybron Dental Specialties, Romulus, MI) in group “A” and with AH Plus cement (DeTrey Dentsply GmbH, Konstanz, Germany) in group “B” and then inserted with tug back into the root canal.

The cone was cut with the Touch’n Heat device (Analytic Technology, Redmond, WA) at the orifice, and then most of the gutta-percha cone was removed with a size 1 Gates-Glidden bur (Dentsply Maillefer)

(15) without water spray on a contra-angle hand piece (Intracompact 2068LHC; Kavo GmbH & Co, Biberach, Germany). Only the most apical 3 to 4 mm of the GT Tulsa cone were left, which were pushed 1 mm apically with a single-compaction movement using a #30 finger plugger (F.K.G. Dentaire) (15).

A size MF gutta-percha cone (Mynol; Block Drug Corporation, Jersey City, NJ) was subsequently placed in the root canal. A #25 stainless steel Gutta-Condensor (Dentsply Maillefer) was used at 8,000 to 10,000 rpm for 5 to 10 seconds (24) to push the gutta-percha against the GT Tulsa apical plug. The Gutta-Condensor was pushed to within 5 mm of the apex to prevent the GT Tulsa gutta-percha from heating. Thermomechanical and manual compaction were performed until the canal was filled.

The cavity access was sealed with Ketac Silver (3M ESPE Dental Products, St Paul, MN), and standardized radiographs were taken for each tooth in buccolingual and mesiodistal projection. After immersion in saline solution for 24 hours, the teeth were rinsed under tap water and subsequently immersed for 14 days in the following demineralizing solution: 7% formic acid, 3% hydrochloric acid, and 8% sodium citrate in aqueous solution (25). The solution was changed every 3 days, and the specimens were kept under continuous agitation (Agitator 722; Asal srl, Milan, Italy). Specimens were rinsed in running tap water for 2 hours; immersed in 99% acetic acid overnight, rinsed in distilled water; dehydrated in ascending concentrations of ethanol at 25%, 50%, 70%, 90%, 95%, and 100% (30-minute passage each); and finally cleared and stored in methyl salicylate (25).

The morphologic analysis was made with the stereomicroscope equipped with a calibrated grid and a micrometer by two examiners selected before commencing the study and who followed well-defined instructions. When the two examiners disagreed, the specimen was subjected to joint evaluation.

The following measures were taken: apex diameter; distance between apex and apical limit of the filling (ie, filling precision) from the buccal aspect; and voids in the filling, in the most apical 4 mm and from 12 to 4 mm from the apex from buccal, lingual, mesial, and distal views.

According to Venturi and Breschi (26), the length of the voids (VL) corresponds to the sum of all the lengths of the voids observed, whereas the width of the voids (VW) corresponds to the width of the widest single empty space. Lateral canals in the most apical 4 mm, from 4 to 8 and from 8 to 12 mm from the apex, were counted and observed from buccal, lingual, mesial, and distal views and their inner diameters as well as every unfilled space within them were measured. To evaluate the filling of lateral canals, five filling ratings were fixed, according to previous studies (26, 27): (1) grade 0: filled with cement up to 10% of their total length; (2) grade 1: filled with cement not up to their total length or

**TABLE 1.** Filling Precision, Voids Length, and Voids Maximal Width in Main Canals in Group A and Group B

	Filling in the Most Apical 4 mm						Filling From 10 to 4 mm From the Apex					
	Group A		Group B		Total		Group A		Group B		Total	
	Mean (mm)‡	SD	Mean (mm)‡	SD	Mean (mm)‡	SD	Mean (mm)‡	SD	Mean (mm)‡	SD	Mean (mm)‡	SD
Filling precision*	0.12 <sup>a</sup>	0.29	0.02 <sup>b</sup>	0.15	0.06	0.26	—	—	—	—	—	—
Voids length†	0.17 <sup>a</sup>	0.06	0.08 <sup>b</sup>	0.03	0.10 <sup>c</sup>	0.03	5.97 <sup>ab</sup>	2.71	5.66 <sup>ab</sup>	2.54	5.69 <sup>d</sup>	2.31
Voids maximal width†	0.03 <sup>a</sup>	0.01	0.00 <sup>b</sup>	0.00	0.02 <sup>c</sup>	0.01	0.27 <sup>ab</sup>	0.05	0.25 <sup>ab</sup>	0.06	0.26 <sup>d</sup>	0.06

Means with the same superscript letter are not statistically different at  $p \leq 0.05$ .

\*Filling precision was evaluated by the distance between the apex and apical limit of the filling in buccal vision.

†The reported voids length value corresponded to the sum of tracts with absence of filling adaptation to the canal walls. The reported voids maximal width value corresponded to maximum width of the voids. Width and length values were calculated on buccal, lingual, mesial, and distal views. No statistical difference was found between the same perspectives (ie, statistical difference was found about voids on mesial view in group A and B and so on). The reported comparison pertains to the sums of all the values measured on the four views in each group.

‡Means with the same superscript letter are not statistically different at  $p \leq 0.05$ .

**TABLE 2.** Inner Diameters of Lateral Canals in Each Third in Group A and Group B

Inner Diameter	Group A						Group B					
	Apical Third		Middle Third		Coronal Third		Apical Third		Middle Third		Coronal Third	
	<i>n</i>	%	<i>n</i>	%	<i>n</i>	%	<i>n</i>	%	<i>n</i>	%	<i>n</i>	%
<50 μm	19	19.4	8	22.2	10	35.7	22	22.0	7	21.2	10	33.3
50–100 μm	29	29.6	14	38.8	12	42.9	28	28.0	12	36.3	14	46.7
105–150 μm	26	26.5	7	19.4	2	7.1	25	25.0	7	21.2	3	10.0
155–300 μm	18	18.4	6	16.8	3	10.7	18	18.0	5	15.2	2	6.7
>300 μm	6	6.1	1	2.8	1	3.6	7	7.0	2	6.1	1	3.3
Total	98	100	36	100	28	100	100	100	33	100	30	100

three dimensionally (thus, empty spaces were identifiable); (3) grade 2: filled three dimensionally, up to their total length by cement, without presence of gutta-percha, or with gutta-percha up to 50% of their total length; (4) grade 3: filled three dimensionally, up to their total length, by cement in which gutta-percha penetrated from 50 to 90% of their total length (nonetheless, any space unfilled by gutta-percha was completely filled by cement); and (5) grade 4: totally filled with both cement and gutta-percha.

**Statistical Analysis**

The Levene test was used to verify the homogeneity of variance, and a *t* test estimated the homogeneity of the means. Analysis of variance was used to establish whether any of the variables were significant, and the Scheffe post hoc test analyzed the effects through multiple comparisons. A *p* value of 0.05 was established. The filling scores of lateral canals were analysed by using a chi-square test with Yates’s adjustment and with the *p* value set at 0.05.

**Results**

**Main Canals**

The results confirmed group homogeneity. There was no statistical difference between groups for canal length and apical diameter. Table 1 shows higher precision (*p* ≤ 0.05) using AH Plus than using PSC (EWT), but the magnitude has no clinical relevance. In the most apical 4 mm of the filling, the AH Plus group had lower VL (*p* ≤ 0.05) and VW (*p* ≤ 0.05) values (Table 1). Evaluating the main canals filling from 12 to 4 mm from the apex, the data revealed no statistical difference of VL and VW between groups, whereas a statistical difference (*p* ≤ 0.05) was found with the most apical 4 mm (Table 1).

**Lateral Canals**

Homogeneity of the groups was confirmed, as they showed no statistical difference for number of lateral canals. Table 2 shows the

number and percentage of lateral canals having different inner diameters in each third of both groups. Table 3 shows the filling scores of lateral canals in the apical, middle, and coronal thirds of both groups. Regardless of the position, the lateral canals in group B, filled using AH Plus cement, had significantly (*p* ≤ 0.05) higher filling scores than those of group A, filled using PSC (EWT) cement. This significant difference (*p* ≤ 0.05) was found also comparing the lateral canals of each third separately.

Regardless of the group, higher filling scores (*p* ≤ 0.05) were achieved in the lateral canals at the coronal compared with those at the middle and at the apical levels and in addition in the lateral canals at the middle compared with those at the apical levels. Figures 1 and 2 show images and radiographs representative for each of the specimen groups.

**Discussion**

**Main Canals**

Precision was significantly better using AH Plus but without values of clinical relevance. Indeed, precision was high in both groups, probably because of the single-compaction movement performed by pushing the finger plugger 1 mm apically to move only the most apical 3 to 4 mm of the GT Tulsa cone.

Fewer voids have been considered to be a good measure of long-term sealing ability (27–29). Indeed, they more properly measure the quality of three-dimensional filling, which is a sealing prerequisite.

Endodontic sealers have lubricating properties that facilitate the movement of gutta-percha (30), bind it to the canal walls, and flow into the canal irregularities that the gutta-percha cannot reach. These properties vary between sealers (28, 31), which could explain why in this study lesser voids were found in the most apical 4 mm using AH Plus. Similar flow values have been reported for AH Plus and PSC (EWT) (29), but Mutal and Gani (32) observed more frequent and larger pores

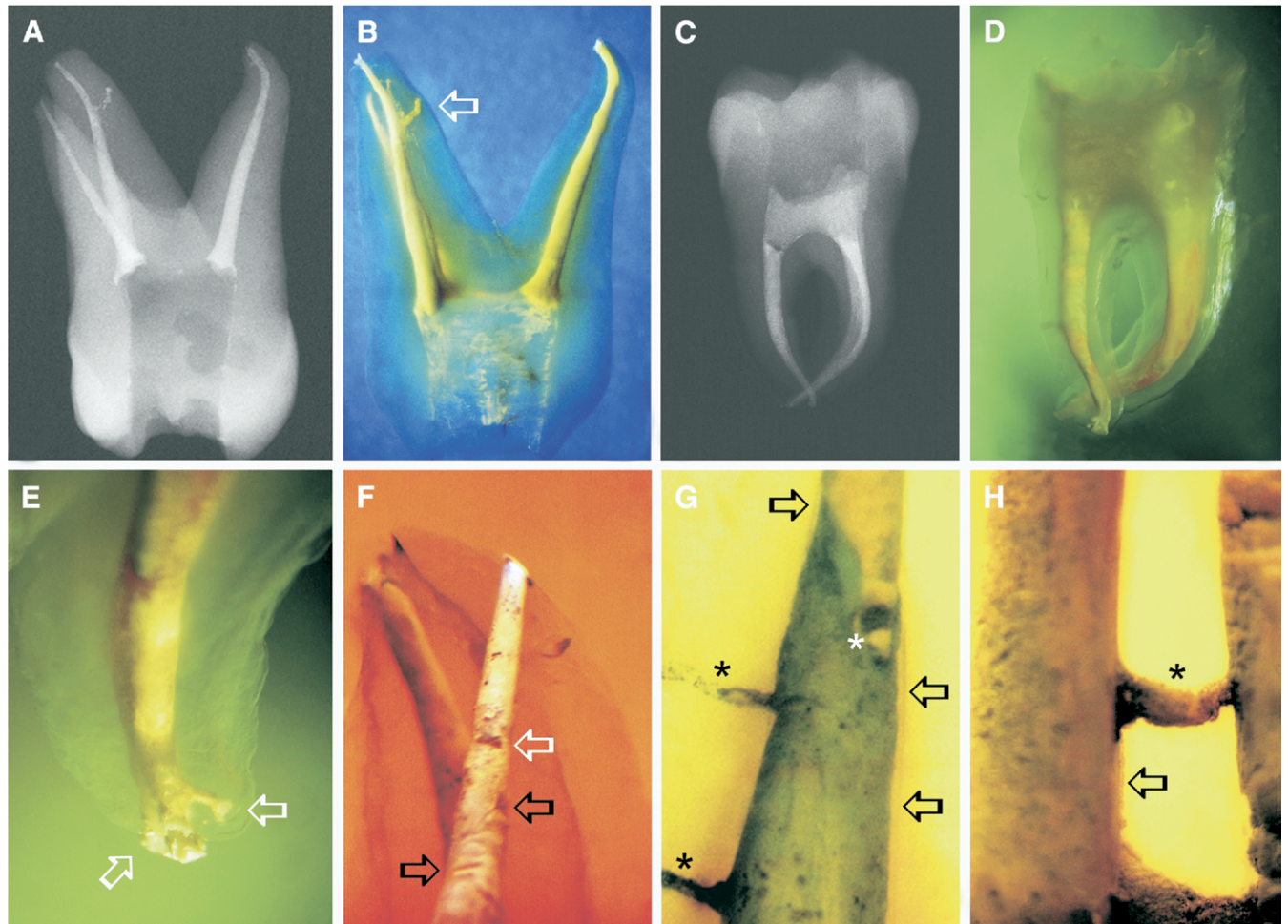
**TABLE 3.** Number of Lateral Canals with Each Filling Score in the Apical, Middle, and Coronal Thirds of Group A (AH Plus) and Group B (Pulp Canal Sealer EWT)

Third*	Group**	Scores					Total N (%)
		0 N (%)	1 N (%)	2 N (%)	3 N (%)	4 N (%)	
Apical <sup>a</sup>	A <sup>ad</sup>	73 (75)	16 (16)	6 (6)	3 (3)	0 (0)	98 (100)
	B <sup>ae</sup>	59 (59)	25 (25)	10 (10)	5 (5)	1 (1)	100 (100)
Middle <sup>b</sup>	A <sup>bf</sup>	23 (64)	8 (22)	4 (11)	1 (3)	0 (0)	36 (100)
	B <sup>bf</sup>	10 (31)	7 (21)	7 (21)	5 (15)	4 (12)	33 (100)
Coronal <sup>c</sup>	A <sup>cg</sup>	3 (11)	7 (25)	15 (53)	2 (7)	1 (4)	28 (100)
	B <sup>cg</sup>	1 (3)	5 (17)	11 (37)	8 (26)	5 (17)	30 (100)
Total	A + B	169 (52)	68 (21)	53 (16)	24 (7)	11 (4)	325 (100)

NOTE.

\*Thirds with the same superscript letter are not statistically different at *p* ≤ 0.05.

\*\*Groups with the same superscript letter are not statistically different at *p* ≤ 0.05.

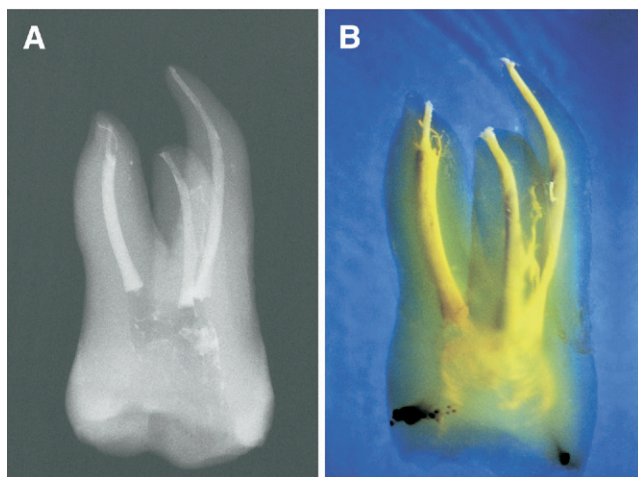


**Figure 1.** (A) A radiograph and (B) photograph after clearing of a maxillary molar filled with the vertical compaction with the apical backfilling technique (VCAB) using AH Plus that show either a homogeneous filling of main canals as well the partial filling of apical lateral canals (arrows) in the mesial-buccal root; (C) a radiograph and (D) photograph after clearing of a mandibular molar filled with the vertical compaction the apical backfilling technique (VCAB) using PCS (EWT); (E) a photograph after clearing of the apical third of the distal root of the previous teeth, showing two apical lateral canals filled with sealer (arrows); (F) photograph after clearing of the apical and middle third of a main root canal filled with VCAB using PCS (EWT), showing either a great void (white arrow) at the limit between the cold-compacted GT Tulsa plug and the backfilling as well other voids on the surface of the backfilled volume (black arrows); (G) a photograph after clearing of the middle third of a main root canal filled with VCAB using PCS (EWT), showing a circular void (white asterisk), two lateral canals partially filled with sealer (black asterisks), and finally two elongated spaces between the filling and the canal walls (black arrows); (H) photograph after clearing of the coronal third of a main root canal filled with VCAB using PCS (EWT), showing an accessory communicating canal (black asterisk) and an elongated space between the filling and the canal wall (black arrow).

and vacuoles in zinc oxide eugenol–based sealers than in resins sealers, suggesting that this finding might be attributed to greater viscosity in the former and more flowing in the latter. Flow is shear dependent and influenced by the viscosity of the material and the temperature (29). For simple Newtonian fluids, viscosity decreases with an increase in temperature; for complex fluids, such as setting pastes, this effect may be much more pronounced (33). Interactions between gutta-percha and sealers also have been reported. A softening effect of AH-26 on most brands of gutta-percha that resulted in increased flow has been observed (16). This was probably because of the liquid of AH-26, bisphenol-A-diglycidylether, the primary chemical building block for a broad spectrum of epoxy resins including AH Plus (19), which appears to act as a partial solvent of gutta-percha (16).

However, no difference concerning voids was found when using AH Plus or PCS (EWT) in the backfilled middle-coronal thirds. On the contrary, in both groups, regardless of the sealer used, significantly greater VL and VW values were found in the backfilled middle-coronal thirds than in the most apical 4 mm.

The vertical compaction with the apical backfilling technique provides the apical compaction of cold gutta-percha and the backfilling with heated gutta-percha in the remaining parts of root canals. With Schilder's technique, something similar occurs because the temperature of the apical gutta-percha usually does not exceed 40° to 42°C (34) so it cannot be plasticized (10), whereas in the middle-coronal thirds plasticizing temperatures of 50° to 80°C were recorded (34). In root canals with maintained apical patency, from a rheologic viewpoint, amorphous gutta-percha should not be compacted close to the apex (10). Amorphous gutta-percha heated above 45°C undergoes molecular transformations that result in shrinking on cooling (12). Shrinking needs to be counteracted by prolonged, firm compaction (12). However, when compacted, amorphous gutta-percha like any non-Newtonian fluid of high viscosity that deforms continuously under a shearing stress conforms to the internal surface of the root canal system and mainly moves to where the resistance is least (ie, through the apex). Thus, shrinking cannot be contrasted. Conversely, if the most apical part of a gutta-percha cone in crystalline state is forced to fit more apically



**Figure 2.** (A) A radiograph and (B) photograph after clearing of a maxillary molar filled with VCAB using AH Plus. The backfilled areas show some filled lateral canals.

within a tapered main canal, a wedge effect occurs that compresses the cone against the canal walls, also counteracting extrusion through the resulting friction (10, 35). Main canals usually have a circular or slightly oval apical section (21). The enlargement obtained in this study with nickel-titanium rotary instruments was probably sufficient to provide a uniform apical .04 taper and a good preliminary cone fitting so that the wedge effect resulted in effective pressing of the gutta-percha against the canal walls and squeezing the sealer coating, thereby reducing the voids (10, 35).

The vertical compaction with the apical backfilling technique provides the backfilling with thermomechanical compaction against the cold compacted GT Tulsa apical plug. A Gutta-Condensor plasticizes Mynol cones sufficiently for it to melt the two types of gutta-percha together and to backfill effectively and, pushed to within 5 mm of the apex, is at such a distance that it is unable to appreciably affect the most apical GT Tulsa gutta-percha, which also softens at a higher temperature than the Mynol cones (10). Most of the voids in the backfilling appeared as long and narrow spaces alongside the canal walls, suggesting the idea that they could have been caused by shrinkage. Indeed, the possibility that shrinkage of heated gutta-percha may be counteracted by compaction (12) has never been investigated. Other roundish voids, observed at 3 to 4 mm from the apex, may have been caused by the finger pluggers. When compacted, cold gutta-percha deforms little. Compaction close to the apex is desirable to obtain sealing (26, 36–38), but empty apical spaces may be left within the filling (26, 39) that are difficult to refill.

### Lateral Canals

Whatever the group, this study achieved higher filling scores in the lateral canals at the coronal levels compared with those at the middle and at the apical levels and in addition in the lateral canals at the middle compared with those at the apical levels. These results are consistent with previous studies reporting that gutta-percha could enter wide coronal accessory canals, whereas narrow apical lateral canals were more frequently and mostly incompletely penetrated by sealer (8, 9, 25, 27, 40, 41).

These results might suggest that the idea of compacting close to the apex cold rather than heated gutta-percha is questionable because even if the gutta-percha is pressed against the canal walls it deforms little (10) and only the sealer is squeezed into the lateral canals. However, from a rheologic viewpoint, compacting the apical gutta-percha at high

plasticizing temperatures is not an advantageous alternative (10). Within a complex root canal system, amorphous gutta-percha and sealers behave as fluids each one flowing differently within a network of circular pipes having different diameters. The volume flow rate of fluids is inversely proportional to viscosity (stickier fluids flow more slowly) as well as to surface roughness and is directly proportional to pressure and to the radius of the pipe. The Hagen-Poiseuille equation, which is a physical law that describes slow viscous laminar flow of Newtonian incompressible fluids through a constant circular cross-section, states that the volume flow rate is proportional to the fourth power of the radius of the pipe. This means that if we halve the diameter of a pipe, we need 16 times as much pressure to maintain the same flow rate. Endodontic sealers and gutta-percha are viscous and highly viscous non-Newtonian fluids, respectively, having less ability to flow than Newtonian fluids. Obviously, it is impossible to predict exactly what occurs within the canal system when the filling materials are heated and compacted, but under compaction a plastic mass of gutta-percha forced to flow moves mainly where the resistance is lowest, in other words through the apex if apical patency is maintained. In this condition, the probability that plasticized apical gutta-percha would enter and fully fill ramifications that often have diameters less than 100  $\mu\text{m}$  (27) is unrealistic (10, 13) and only the sealer, because of its lower viscosity and higher flow, can penetrate narrow apical ramifications.

The better filling scores found in the middle-coronal lateral canals were achieved by the thermomechanical compaction of Mynol cones against the cold compacted GT Tulsa apical plug, which minimized the risk of apical extrusion. Thus, protracted thermomechanical compaction could mix gutta-percha and cement, provided a homogeneous backfilling in main canals and diverted the vertical compaction forces against the lateral walls. This effectively pushed gutta-percha and cement into the middle-coronal ramifications (27), which are generally wider than the apical ones.

Regardless of the position, as well as comparing each third separately, the lateral canals in group “B,” in which AH Plus was used, had higher filling scores than those in group “A,” in which PCS (EWT) was used. Once more, the differing physical properties of the sealer used (32) and its interactions with the gutta-percha brands used (16) need to be taken into account. AH Plus is slightly thixotropic and thermoplastic (19), and it can be hypothesized that AH Plus became more fluid than PCS (EWT) when heated and/or compacted. Fluidity enhances the ability of the filling materials to penetrate into root canal ramifications (25), and this might explain the results found. However, further research should be conducted regarding the responses of different sealers to different realistic conditions.

In conclusion, when using the vertical compaction with the apical backfilling technique with either AH Plus or PCS (EWT), the apical gutta-percha cold compaction provided lesser voids than the middle-coronal thermomechanical compaction as well as lower filling scores in the apical lateral canals. The same technique, when used with AH Plus rather than PCS (EWT), provided lesser voids in the apical third and, regardless of the canal third, better filling scores in the lateral canals.

### Acknowledgments

*The author express his gratitude to Dr. Giulia Habib for her assistance in the statistical analysis, and to Prof. Robert Husband for his scientific support.*

### References

1. Nguyen NT. Obturation of the root canal system. In: Cohen S, Burns RC, eds. *Pathways of the pulp*, 4th ed. St Louis, MO: Mosby; 1987;183–94.
2. De Deus QD. Frequency, location, and direction of lateral, secondary, and accessory canals. *J Endod* 1975;1:361–6.

3. Barthel CR, Zimmer S, Trope M. Relationship of radiologic and histologic signs of inflammation in human root-filled teeth. *J Endod* 2004;30:75–9.
4. Seltzer S, Bender IB, Ziontz M. The interrelationship of pulp and periodontal disease. *Oral Surg Oral Med Oral Path Oral Radiol Endod* 1963;16:1474–90.
5. Seltzer S, Bender IB, Smith J, Freedman I, Nazimov H. Endodontic failures—an analysis based on clinical, roentgenographic, and histologic findings. I. *Oral Surg Oral Med Oral Path Oral Radiol Endod* 1967;23:500–16.
6. Weine FS. The enigma of the lateral canal. *Dent Clin North Am* 1984;28:833–52.
7. Ingle JI, Newton CW, West JD, et al. Obturation of the radicular space. In: Ingle JI, Bakland LK, eds. *Endodontics*, 5th ed. Hamilton, Ontario: BC Decker; 2002;579–96.
8. Schilder H. Filling root canals in three dimensions. *Dent Clin North Am* 1967;11:723–44.
9. Reader CM, Himel VT, Germain LP, Hoen MM. Effect of three obturation techniques on the filling of lateral canals and the main canal. *J Endod* 1993;19:404–8.
10. Venturi M, Di Lenarda R, Breschi L. An ex vivo comparison of three different gutta-percha cones when compacted at different temperatures: rheological considerations in relation to the filling of lateral canals. *Int Endod J* 2006;39:648–56.
11. Collins J, Walker MP, Kulild J, Lee C. A comparison of three gutta-percha obturation techniques to replicate canal irregularities. *J Endod* 2006;32:762–5.
12. Schilder H, Goodman A, Aldrich W. The thermomechanical properties of gutta-percha. Part V. Volume changes in bulk gutta-percha as a function of temperature and its relationship to molecular phase transformation. *Oral Surg Oral Med Oral Path Oral Radiol Endod* 1985;59:285–96.
13. Clinton K, Van Himel T. Comparison of a warm gutta-percha obturation technique and lateral condensation. *J Endod* 2001;27:692–5.
14. Peng L, Ye L, Tan H, Zhou X. Outcome of root canal obturation by warm gutta-percha versus cold lateral condensation: a meta-analysis. *J Endod* 2007;33:106–9.
15. Venturi M. Evaluation of canal filling after using two warm vertical gutta-percha compaction techniques in vivo: a preliminary study. *Int Endod J* 2006;39:538–46.
16. Tagger M, Greenberg B, Sela G. Interaction between sealers and gutta-percha cones. *J Endod* 2003;29:835–7.
17. Carvalho-Júnior JR, Guimarães LF, Correr-Sobrinho L, Pécora JD, Sousa-Neto MD. Evaluation of solubility, disintegration, and dimensional alterations of a glass ionomer root canal sealer. *Braz Dent J* 2003;14:114–8.
18. Tagger M, Tagger E, Tjan AH, Bakland LK. Measurement of adhesion of endodontic sealers to dentin. *J Endod* 2002;28:351–4.
19. DeTrey Dentsply GmbH. Scientific Compendium AH Plus 050419 rMV exl.doc, Dentsply DeTrey, GmbH, Konstanz, Germany; 2005.
20. Schneider SW. A comparison of canal preparations in straight and curved root canals. *Oral Surg Oral Med Oral Path Oral Radiol Endod* 1971;32:271–5.
21. Marroquín BB, El-Sayed MA, Willershausen-Zönnchen B. Morphology of the physiological foramen: I. Maxillary and mandibular molars. *J Endod* 2004;30:321–8.
22. Dummer PM, McGinn JH, Rees DG. The position and topography of the apical canal constriction and apical foramen. *Int Endod J* 1984;17:192–8.
23. Goldberg F, Spielberg C. The effect of EDTAC and the variation of its working time analyzed with scanning electron microscopy. *Oral Surg Oral Med Oral Path Oral Radiol Endod* 1982;53:74–7.
24. McSpadden J. Self study course for the thermatic condensation of gutta-percha. Toledo, OH: Ransom and Randolph; 1980.
25. Venturi M, Prati C, Capelli G, Falconi M, Breschi L. A preliminary analysis of the morphology of lateral canals after root canal filling using a tooth-clearing technique. *Int Endod J* 2003;36:54–63.
26. Venturi M, Breschi L. Evaluation of apical filling after warm vertical gutta-percha compaction using different procedures. *J Endod* 2004;30:436–40.
27. Venturi M, Di Lenarda R, Prati C, Breschi L. An in vitro model to investigate filling of lateral canals. *J Endod* 2005;31:877–81.
28. Weis MV, Parashos P, Messer HH. Effect of obturation technique on sealer cement thickness and dentinal tubule penetration. *Int Endod J* 2004;37:653–63.
29. Almeida JF, Gomes BP, Ferraz CC, Souza-Filho FJ, Zaia AA. Filling of artificial lateral canals and microleakage and flow of five endodontic sealers. *Int Endod J* 2007;40:692–9.
30. Wu MK, van der Sluis LW, Wesselink PR. A preliminary study of the percentage of gutta-percha-filled area in the apical canal filled with vertically compacted warm gutta-percha. *Int Endod J* 2002;35:527–35.
31. Siqueira JF Jr, Rôças IN, Favieri A, Abad EC, Castro AJ, Gahyva SM. Bacterial leakage in coronally unsealed root canals obturated with 3 different techniques. *Oral Surg Oral Med Oral Pathol Oral Radiol Endod* 2000;90:647–50.
32. Mutal L, Gani O. Presence of pores and vacuoles in set endodontic sealers. *Int Endod J* 2005;38:690–6.
33. Barnes HA. Viscosity. Aberystwyth, UK: The University of Wales Institute of Non-Newtonian Fluid Mechanics, 2002.
34. Marlin J, Schilder H. Physical properties of gutta-percha when subjected to heat and vertical condensation. *Oral Surg Oral Med Oral Path Oral Radiol Endod* 1973;36:872–9.
35. Lugassy AA, Yee F. Root canal obturation with gutta-percha: a scanning electron microscope comparison of vertical compaction and automated thermatic condensation. *J Endod* 1982;8:120–5.
36. Allison DA, Michelich RJ, Walton RE. The influence of master cone adaptation on the quality of the apical seal. *J Endod* 1981;7:61–5.
37. Bowman CJ, Baumgartner JC. Gutta-percha obturation of lateral grooves and depressions. *J Endod* 2002;28:220–3.
38. Jung IY, Lee SB, Kim ES, Lee CY, Lee SJ. Effect of different temperatures and penetration depths of a System B plugger in the filling of artificially created oval canals. *Oral Surg Oral Med Oral Path Oral Radiol Endod* 2003;96:453–7.
39. Jurcak JJ, Weller RN, Kulild JC, Donley DL. In vitro intracanal temperatures produced during warm lateral condensation of gutta-percha. *J Endod* 1992;18:1–3.
40. DuLac KA, Nielsen CJ, Tomazic TJ, Ferrillo PJ Jr, Hatton JF. Comparison of the obturation of lateral canals by six techniques. *J Endod* 1999;25:376–80.
41. Silver GK, Love RM, Purton DG. Comparison of two vertical condensation obturation techniques: Touch'n Heat modified and System B. *Int Endod J* 1999;32:287–95.