

Endodontic Retreatment of Mandibular Molar Teeth with Large Diameter Periapical Lesions: A Case Report

***Assist. Prof. Dr. İpek Öreroğlu**, Assist. Prof. Dr. Güneş Karakaya
Department of Endodontics Faculty of Dentistry Bahçeşehir University, Istanbul

Introduction

Management of large periapical lesions associated with failed root canals is a difficult and comprehensive treatment.

Aim

To present the success of retreatment cases after the appropriate treatment protocol was applied.

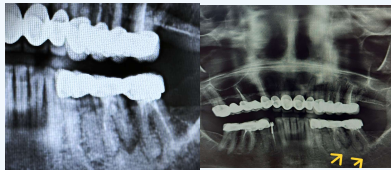


Fig.1: Pre-operative radiographs

Material- Method

Case : A 70-year-old female patient presented asymptotically with a resolved abscess–fistula history in the left mandibular molar region.

Clinical examination revealed a closed sinus tract, poor prosthetic fit, and slight mobility, with no percussion or palpation tenderness for both first and second molars.

Radiographic and CBCT examinations revealed external root resorption and a large periapical lesion at the distal root of the left mandibular first molar, along with a smaller periapical lesion in the left mandibular second molar with inadequate root canal fillings.

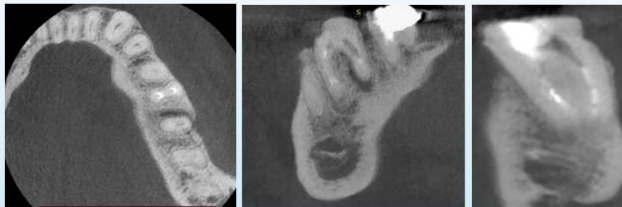


Fig.2:CBCT images after the first treatment session

Nonsurgical root canal retreatment was performed on both teeth under dental operating microscope (Zumax Medical Co., Ltd., China) magnification with rubber dam isolation.

Previous root canal filling materials were removed using rotary (XP Shaper FKG Dentaire, La Chaux-de-Fonds, Switzerland) reciprocating systems (T-Endo MUST files Dentac Co., Ltd., Korea) and ultrasonic instruments. Irrigation was carried out with % 5,25 NaOCl and %17 EDTA, activated using a sonic irrigation (EDDY VDW GmbH, Munich, Germany) system. Working length was measured with an apexlocator (Root ZX Mini, J. Morita Corp., Tokyo, Japan) and verified by periapical radiography. After complete canal debridement, Ca(OH)₂ was placed in the canals. Each tooth was treated in separate sessions.



Fig.3: Treatment Steps



Fig.4: Ultrasonic tip

Fig.5: Dental operating microscope

At the second visit, the patient remained asymptomatic, and no clinical signs of inflammation were observed. Following removal of the medicament and repetition of the irrigation protocol, the absence of inflammatory findings supported completion of the treatment. The canals were obturated using a bioceramic-based sealer and gutta- percha cones. The teeth were temporarily restored with glass ionomer cement and referred to prosthodontic department for permanent coronal restoration.

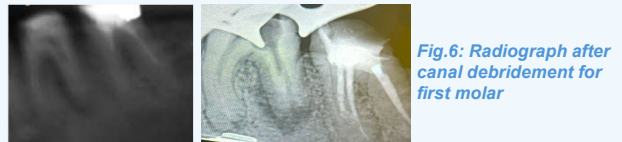

Fig.6: Radiograph after canal debridement for first molar

Fig.7: Working length radiograph of 1st molar and completed root canal treatment radiograph of the 2nd molar.

Results

Postoperative and follow-up radiographs obtained at two months demonstrated initial periapical healing and a reduction in lesion size.

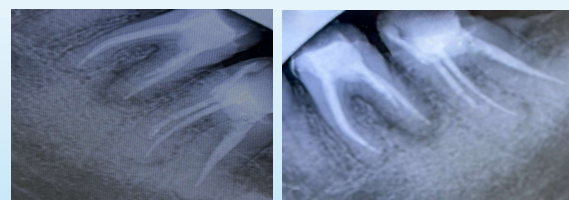


Fig.8: Postoperative radiographs of both teeth obtained from different angulations

Discussion

In this study, both teeth showed a favorable response to retreatment, with follow-up radiographs revealing substantial resolution of the periapical lesion. Following root canal retreatment of first molars, complete resolution of periapical lesions was reported in 71.2% of cases by Jianing et al.(1), whereas Şerefoğlu et al(2). reported a rate of 88%. The results of these studies can be considered consistent with the outcome of the present case, as successful healing was also achieved.

Conclusion

This case supports that nonsurgical endodontic retreatment can be an effective and predictable approach for managing teeth with large periapical lesions, potentially eliminating the need for surgical intervention when appropriate protocols are applied.